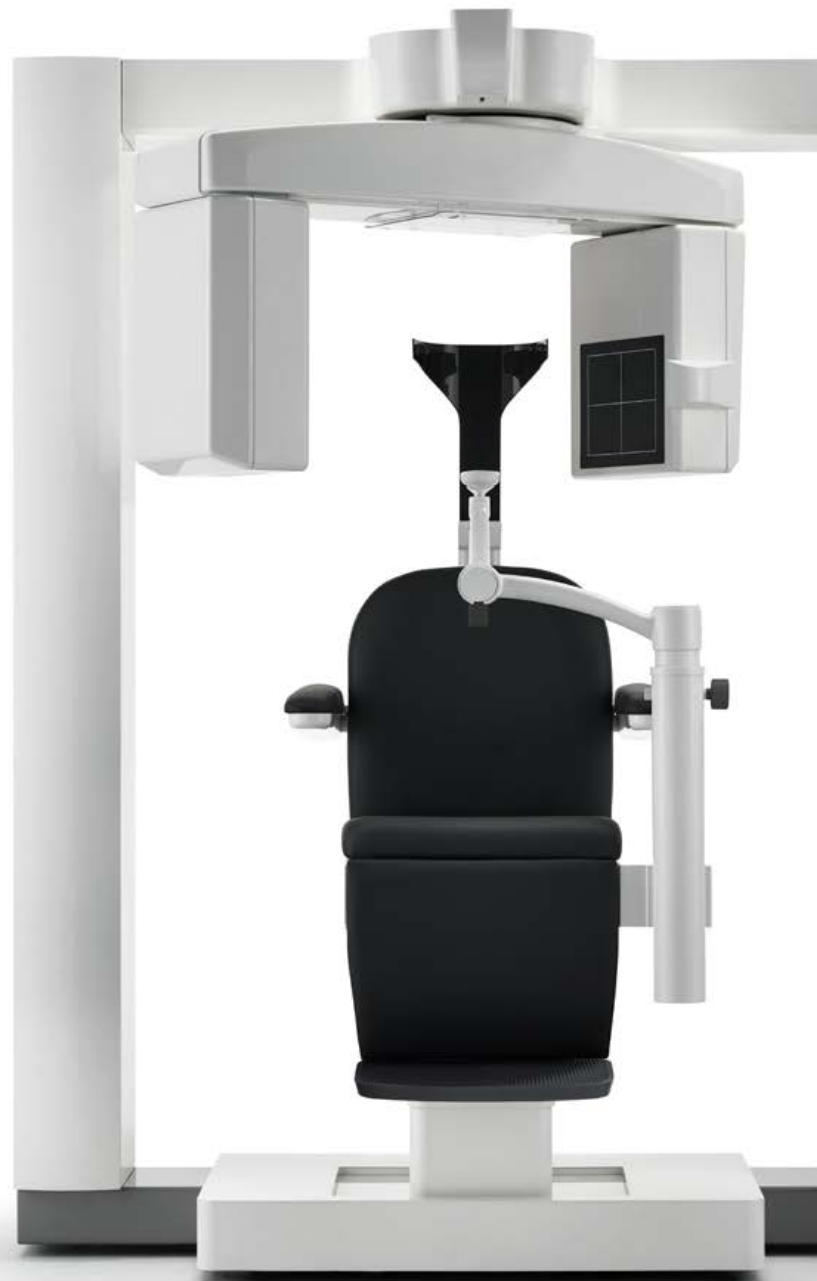



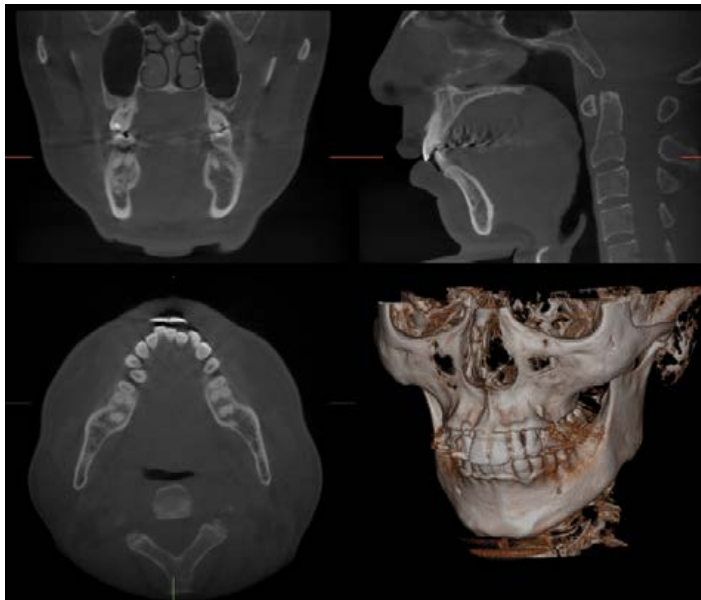
3D Accuitomo 170



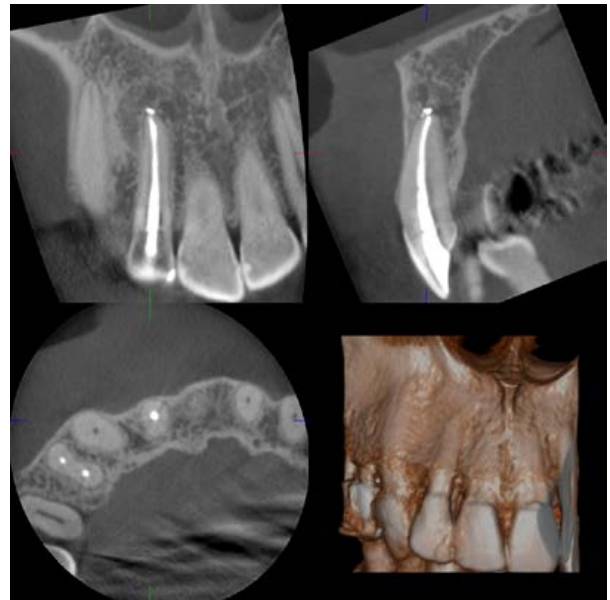3D Accuitomo 170

Unsurpassed image clarity

The 3D Accuitomo 170 offers unsurpassed image clarity. With 9 fields of view and multiple acquisition modes, the 3D Accuitomo 170 can meet all of your diagnostic needs with unparalleled quality. Its super-fine minimal voxel size of just 80µm allows diagnosing even the most subtle details of bone and dentition. The 3D Accuitomo 170 is highly recommended by leading dental radiologists for periodontology, oral surgery, endodontics, orthodontics, dental implants, for the maxillofacial region and beyond.



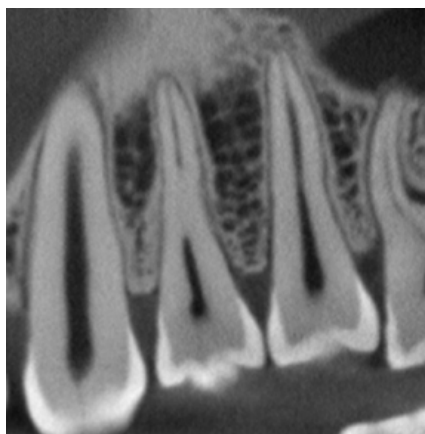
ø170 × H 120 mm (250µm)



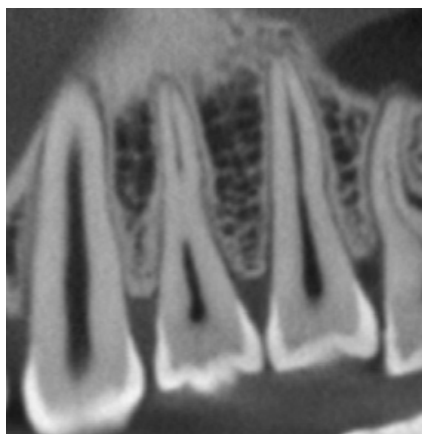
ø40 × H 40 mm (80µm)

Stunning clarity

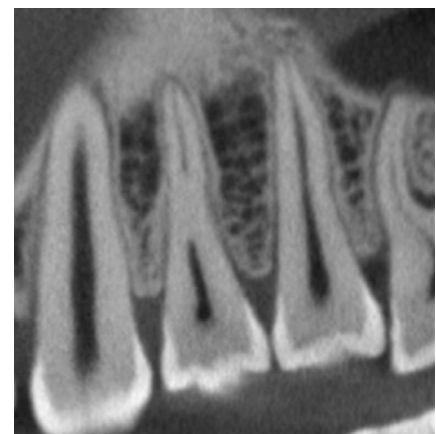
The high resolution 80µm acquisitions provide images of stunning clarity, giving you diagnostic information like you've never seen before. Take your treatment planning to the next level.



High-resolution 360° (80µm)




Standard-resolution 360° (80µm)



High-speed 360° (80µm)

Adaptable Acquisition Modes

The 3D Accuitomo 170 is equipped with four imaging modes that allow flexibility when scanning patients with a variety of diagnostic needs and clinical indications. Choose High Resolution and High Fidelity modes for the best quality images, or High Speed for patients that have difficulty remaining still. The 3D Accuitomo 170 will adapt to suite your diagnostic and your patients' needs.



※ High-Speed Mode is available for $\phi 40 \times H40$ mm and $\phi 60 \times H60$ mm fields of view only.

9 different fields of view can be selected to meet a wide variety of clinical needs. From the smallest, 40 x 40 to the largest 170 x 120, there is a size that fits your needs while always ensuring the lowest X-ray doses possible to the patient. This flexibility allows the 3D Accuitomo 170 to provide stunning images for Endodontics, Periodontics, Maxillofacial surgery and many more.

Standard Mode

360° scan 17.5 sec, 180° scan: 9 sec

Standard mode offers images of exceptional clarity and is suitable for limited and wide views of temporal bone, paranasal, sinus, maxilla and mandible, individual teeth, etc.

High Resolution Mode

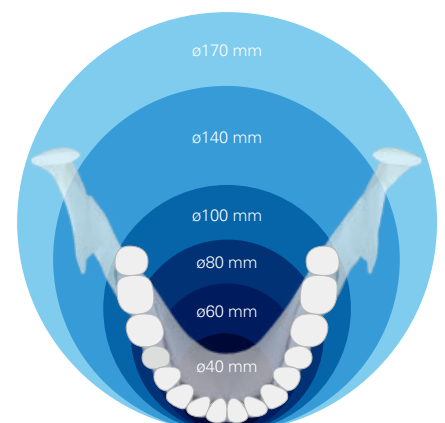
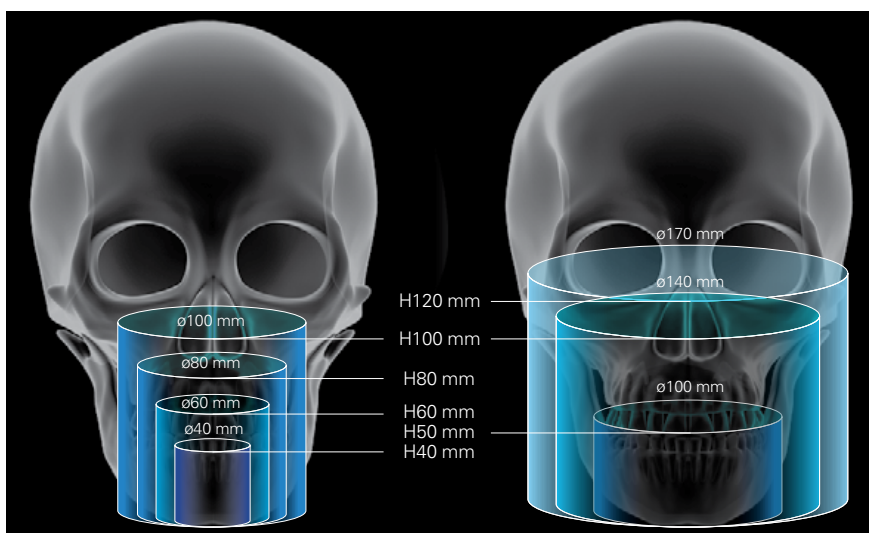
At 1/4 the standard pixel size, high-resolution mode produces the sharpest and clearest images the 3D Accuitomo 170 has to offer. Even in hi-res mode, 360 scans take only 30.8 sec, and 180 scans a mere 15.8 sec. Available for 40 x 40 mm and 60 x 60 mm FOVs.

High Fidelity Mode

Slow and steady scans at 30.8 sec for 360° and 15.8 sec for 180° makes for exceptionally clear images with minimal artifacts. Zoom reconstructions made from this acquisition are exceptionally clear.

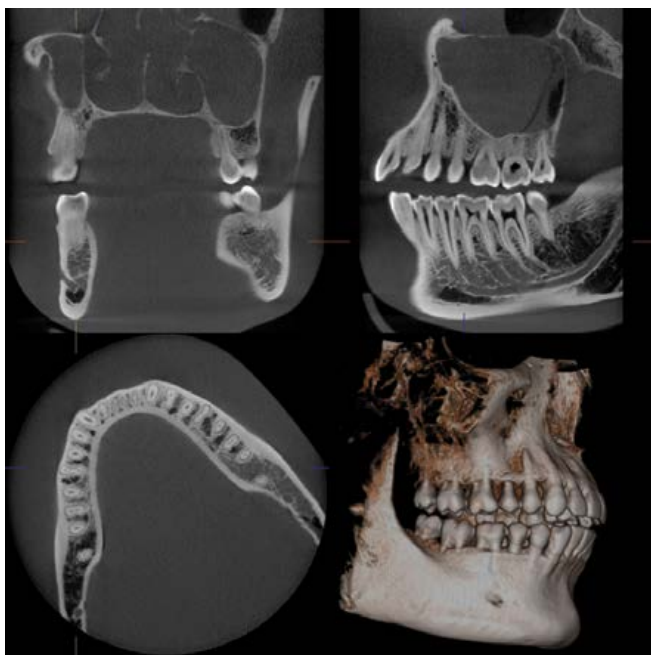
High Speed Mode

360 scan: 10.5 sec, 180 scan: 5.4 sec utilize high speed mode to reduce motion artifacts for patients that may not be able to sit still. It is a good choice for children and for patients concerned with higher X-ray dosage. Available for 40 x 40mm and 60 x 60 mm FOVs.

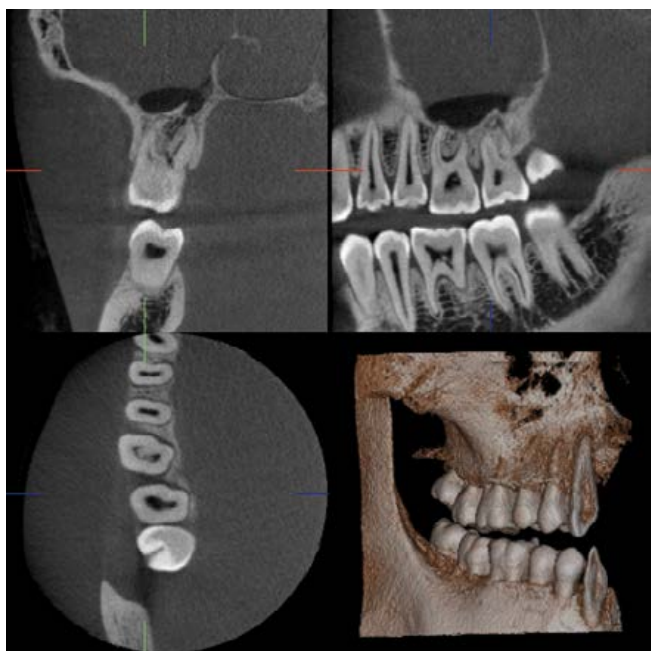
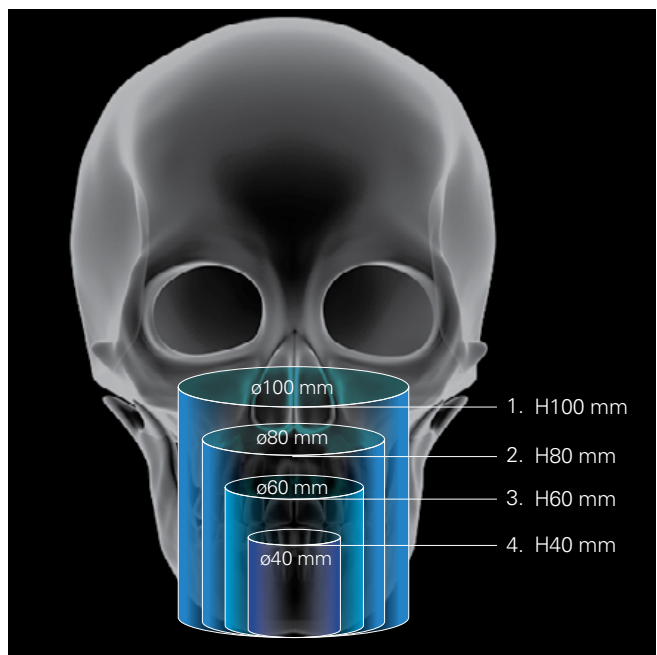


Small Fields of View

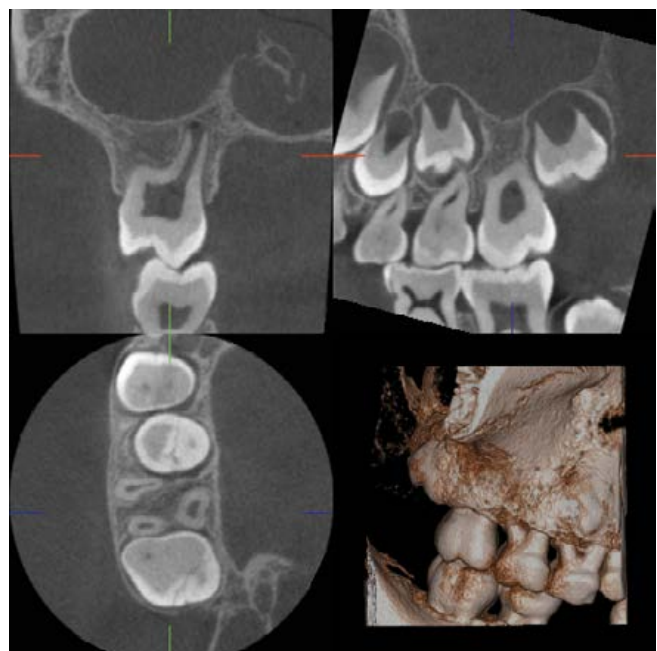Stay focused on your region of interest by selecting the best field of view for your indication. Volume diameters as small as 40 mm or as large as 100 mm can be selected for the dentition.



1. $\varnothing 100 \times H100$ mm (250 μ m)



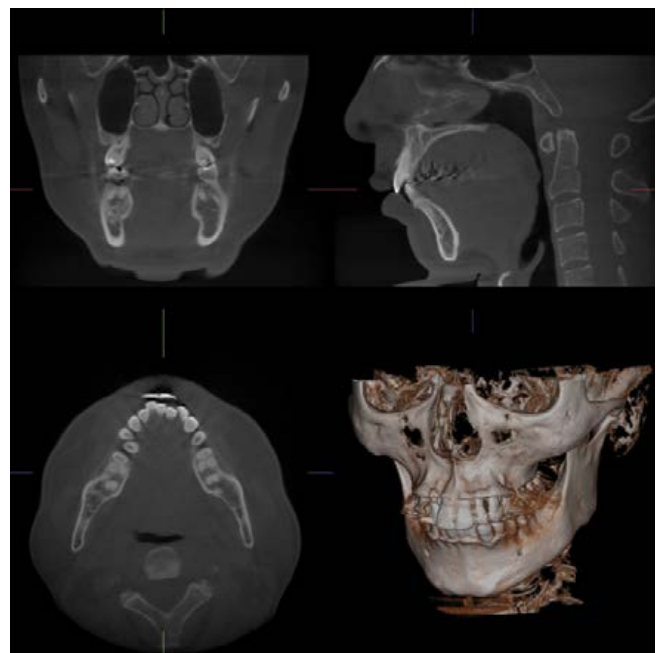
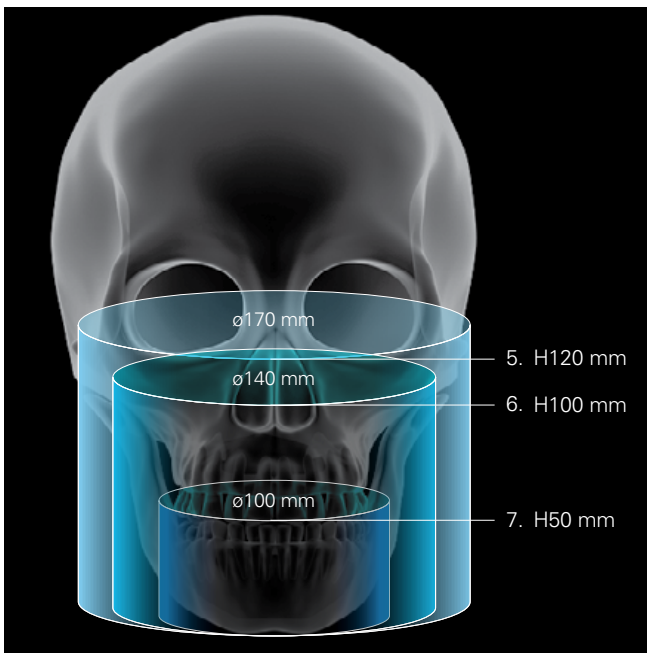
2. $\varnothing 60 \times H60$ mm (125 μ m)



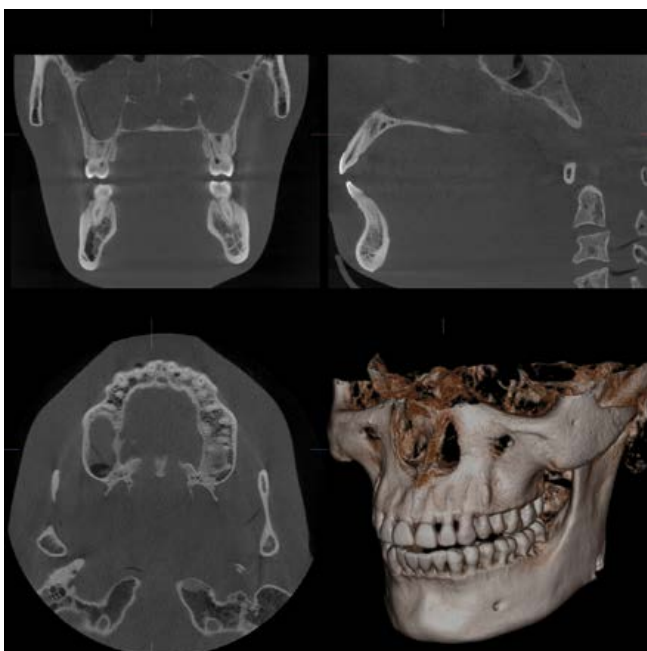3. $\varnothing 40 \times H40$ mm (80 μ m)

Large Fields of View

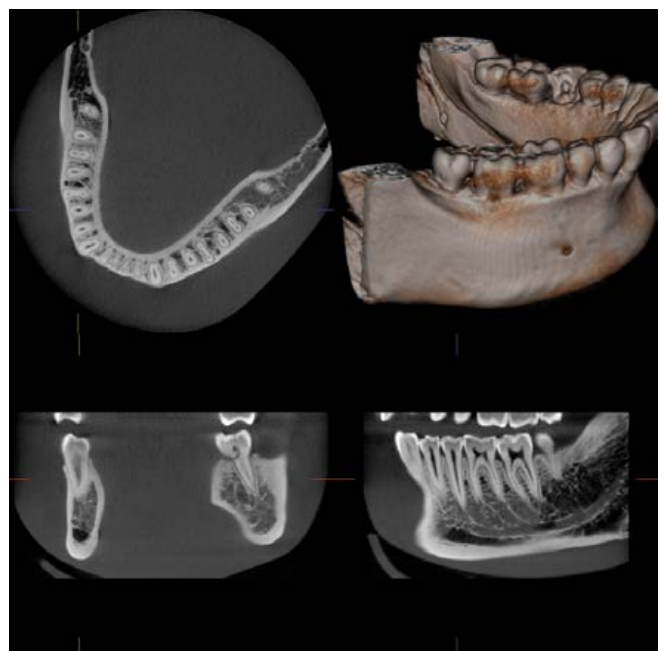
For larger maxillofacial scans, select a diameter of $\phi 100$ to $\phi 170$ to cover a wider range of maxillofacial surgeries.



4. $\phi 170 \times H120$ mm (250 μ m)

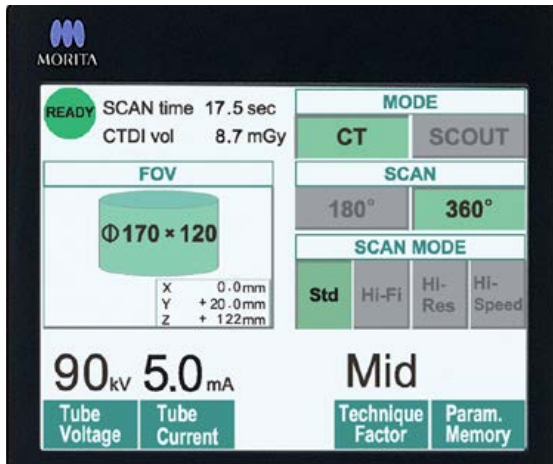


5. $\phi 140 \times H100$ mm (250 μ m)



6. $\phi 100 \times H50$ mm (250 μ m)

Simple, Accurate Positioning

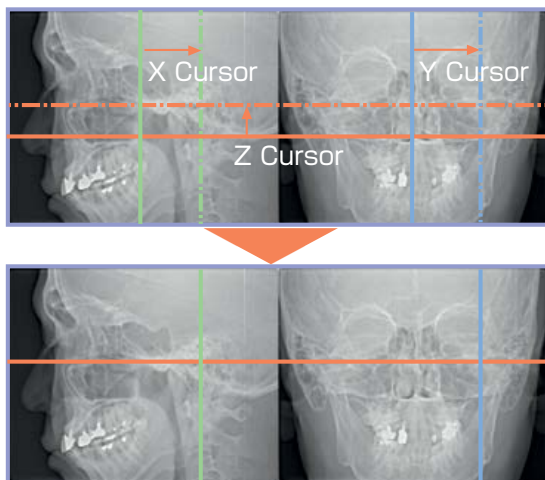


The three positioning laser beams and an LCD make patient positioning easy.

The chinrest stabilizes the patient's head to avoid movement. Scout images enable even more accurate positioning.

Easy as One, Two, Three.

First, the patient's initial position is set and recorded using the three positioning laser beams. Then, the region of interest is aligned in the LCD. The chair automatically moves into the optimal position. During the X-ray exposure, the patient is stabilized by the chinrest and the headrest.

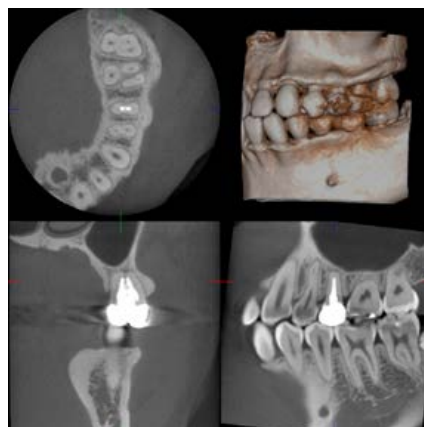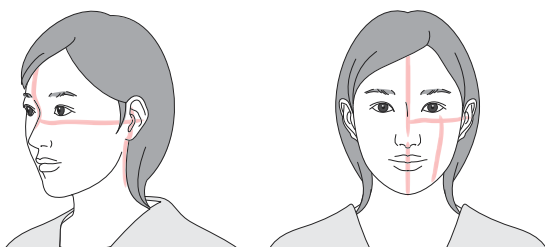


2-direction scout

For even more accurate positioning, scout images can be utilized.

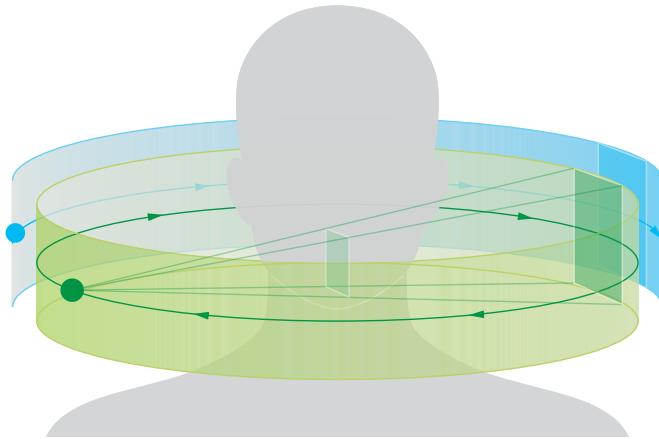
After positioning, two still X-ray images of coronal and sagittal views can be taken to confirm that the position is accurate. If adjustment is necessary, positioning can be changed by dragging the cursor on the monitor and moving it to the center of the region of interest.

The scout exposure (80kV and 2.0 mA) will increase the total X-ray dosage of a Standard Mode CT exposure (90kV and 5.0 mA) by about 2%.



3D-CT image
Region of interest is perfectly positioned.

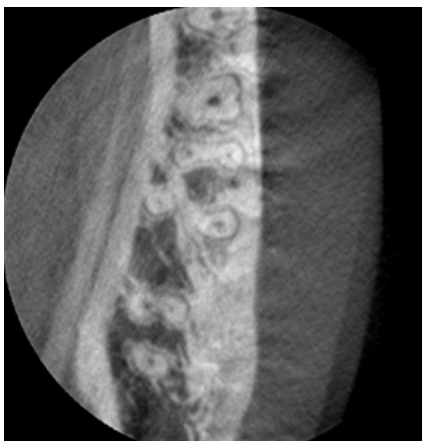Acquisition is only the beginning



180 degree reconstruction to reduce motion artifacts

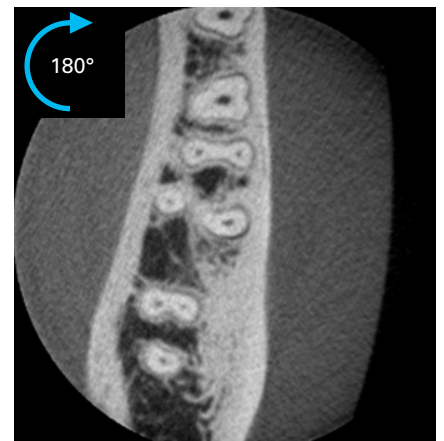
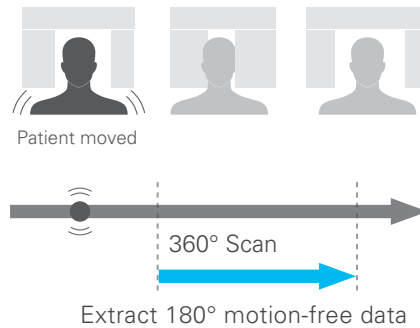
Did the patient move during acquisition? Do you have to scan them again? Not any more! The 3D Accuitomo 170 allows you to extract 1/2 of a 360° scan at any point to remove that initial jolt or that unintended swallow at the end of the acquisition.

(For 360° acquisitions only)

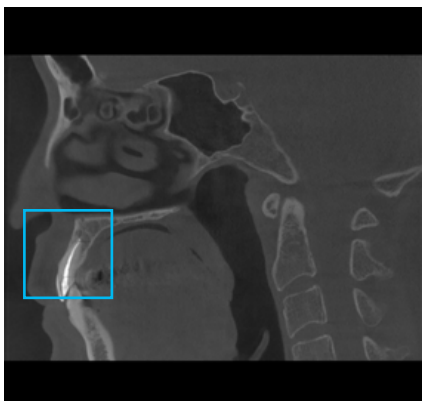


360° scan exhibiting patient movement artifacts

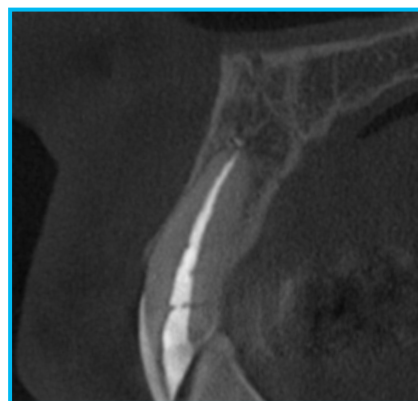
Remove unintended motion artifacts



180° of motion-free data extracted.



Ø170 × H120 mm (250µm)

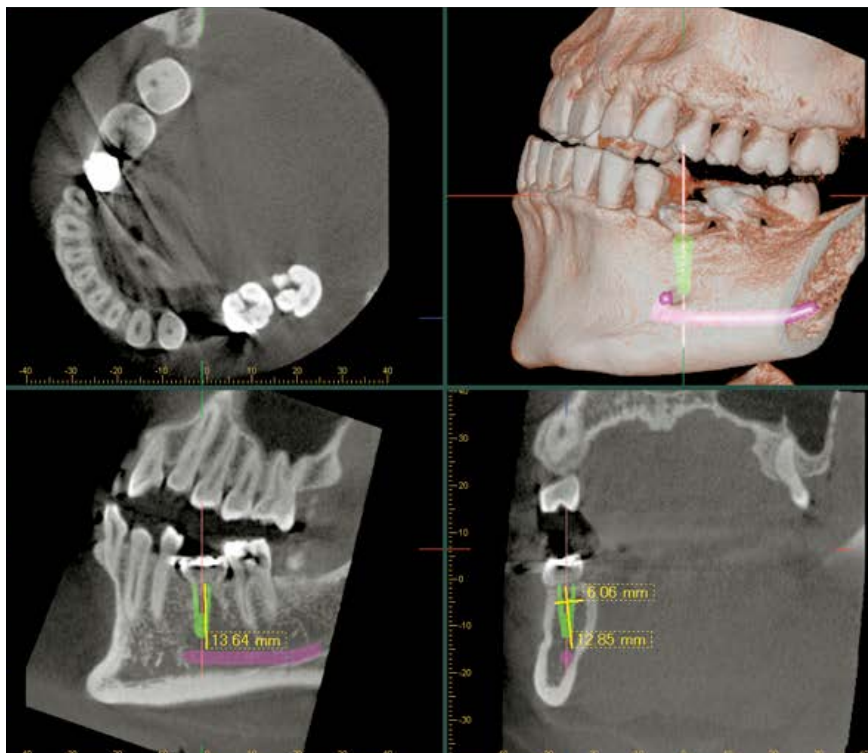


Ø40 × H40 mm (80µm)

Zoom reconstruction

The Accuitomo series is equipped with a unique zoom reconstruction function allowing you to zoom in and reconstruct a new volume from the original scan, without the need for additional acquisitions. The new volume can be reconstructed with a resolution of up to 80µm improving diagnostic accuracy with no additional X-ray exposure to the patient.

i-Dixel

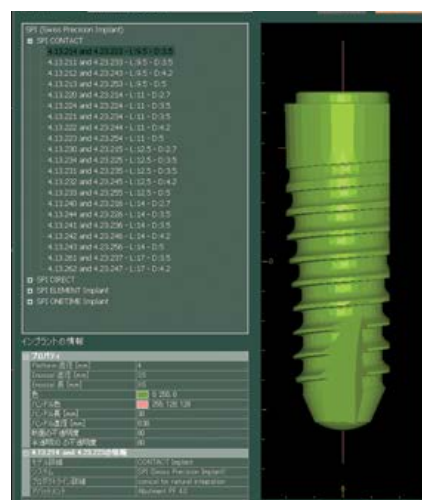
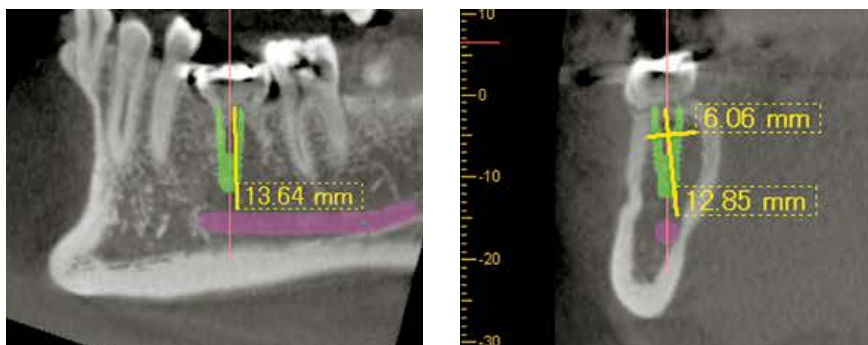


Acquisition to diagnosis made simple

The i-Dixel imaging software offers a wide variety of features to help you quickly and easily create comprehensive treatment plans and explain those plans to your patients. Mandibular canal marking, implant presentation, multiplanar reconstruction are just a few of the features that i-Dixel provides for diagnoses. i-Dixel is also fully DICOM compliant and provides quick and easy integration with both practice management software and advanced treatment planning tools.

Volume Rendering

Volume rendering displays a solid 3D image showing the bone structure and dental arch. The volume rendered image is linked to the slices and moves in real time whenever a slice is adjusted.



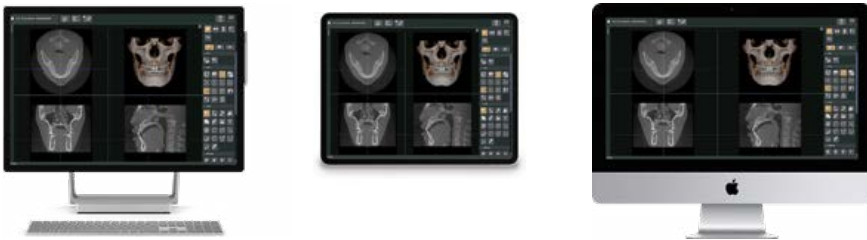From multiplanar reconstructions to implant presentations

Implant Presentation

Select from a variety of popular implant manufacturers and place the implant directly in the CT slice for presentation. This presentation can be easily understood by patients and helps with case acceptance.

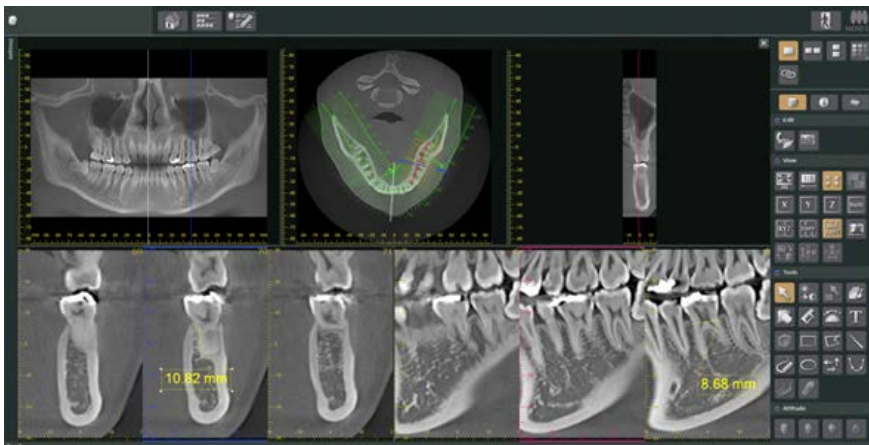


i-Dixel WEB



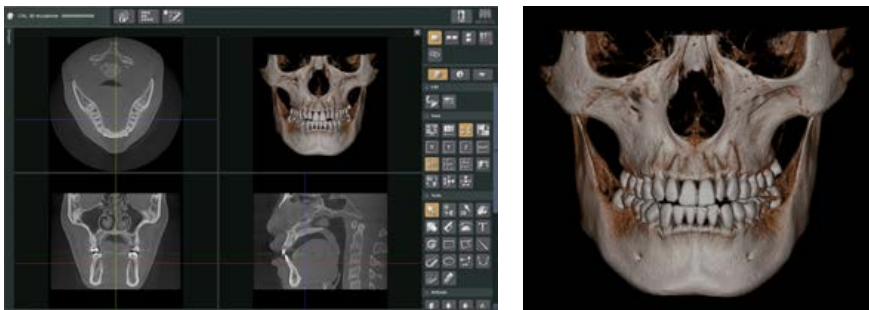
Freedom from platform and simplicity of design

i-Dixel WEB runs as a web service on an X-ray server PC included with your Morita X-ray system. It serves as a local and secure web-based dental image processing service that you can access throughout your practice on a wide range of devices.



No software installation needed

With the latest advancements in web technology, i-Dixel WEB gives you the freedom to view your images wherever you want and however you want. Gone are the days of complicated chairside PC setups, and limited choices of hardware. Mac OS X and even iPads can be used to view and edit data from a Morita X-ray system.



3D image processing

Even though i-Dixel WEB is a fully web-based system, the features you've come to expect are not compromised. View Morita's signature high quality images on the device of your choice!

Mac, iPad, Safari, OS X and Mac OS are trademarks of Apple Inc., registered in the U.S. and other countries. Windows, Windows 8, Windows 10 and Internet Explorer are registered trademarks of Microsoft Corporation in the United States and other countries.

Implantology

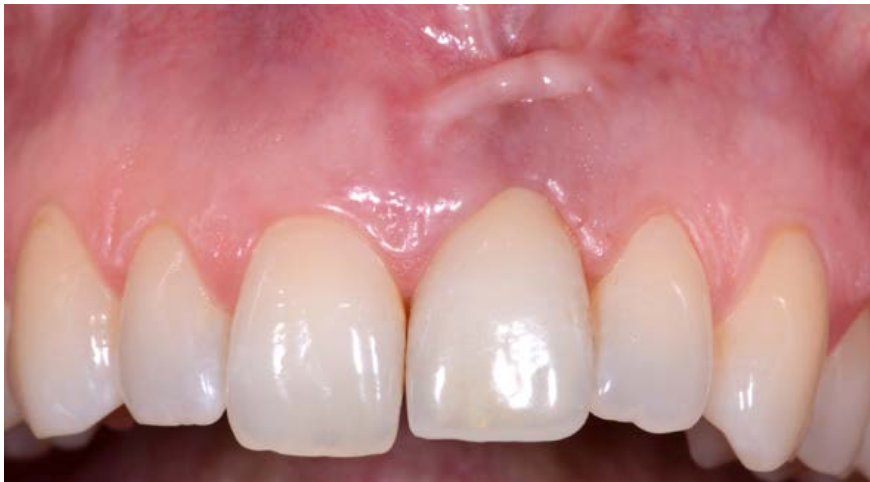

Image 1a: Clinical aspect at the initial examination

Case 1: Female patient referred for 3-dimensional analysis of an esthetic complication in the left maxillary incisor region (a).

The clinical status exhibits a mucosal recession as well as a flattening and discoloration of the facial mucosa at the implant crown. The patient complained about recurrent peri-implant infections.

*: Nasal palate tube

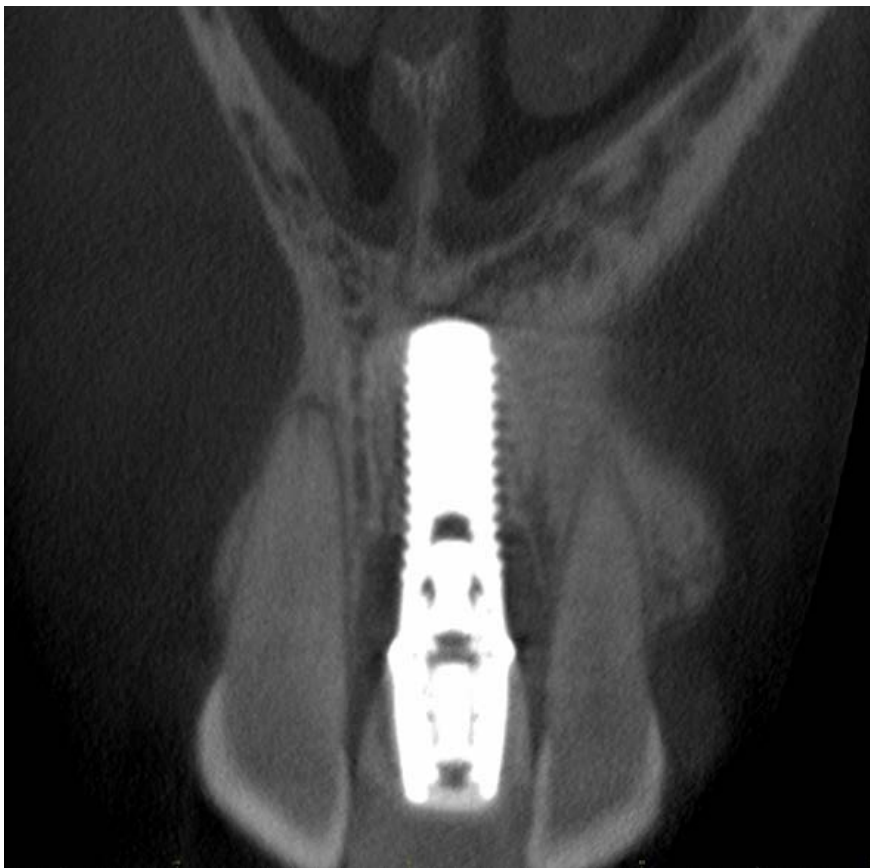

Image 1b: Coronal CBCT slice

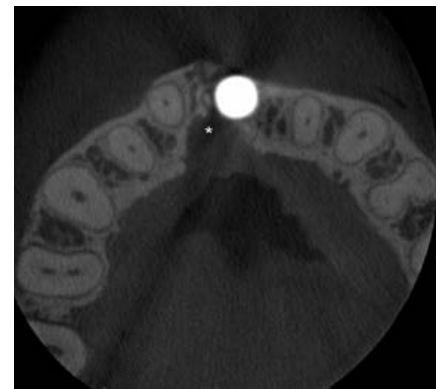

Image 1c: Axial CBCT slice

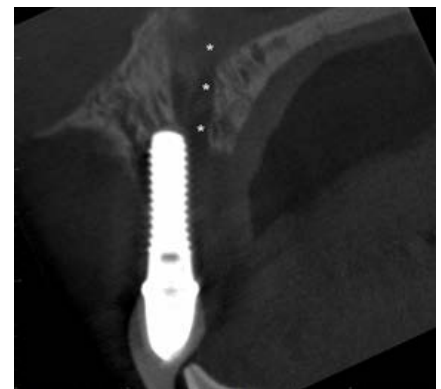

Image 1d: Sagittal CBCT slice

Case courtesy Prof. em. Dr. Daniel Buser, Clinic for oral surgery and somatology University Bern Prof. Dr. Michael Bornstein, Department of Oral Health & Medicine, University Center of Dental Medicine Basel UZB, University of Basel (Switzerland) and Honorary Professor in Oral and Maxillofacial Radiology, Faculty of Dentistry, The University of Hong Kong (Hong Kong SAR, China).

Periodontics

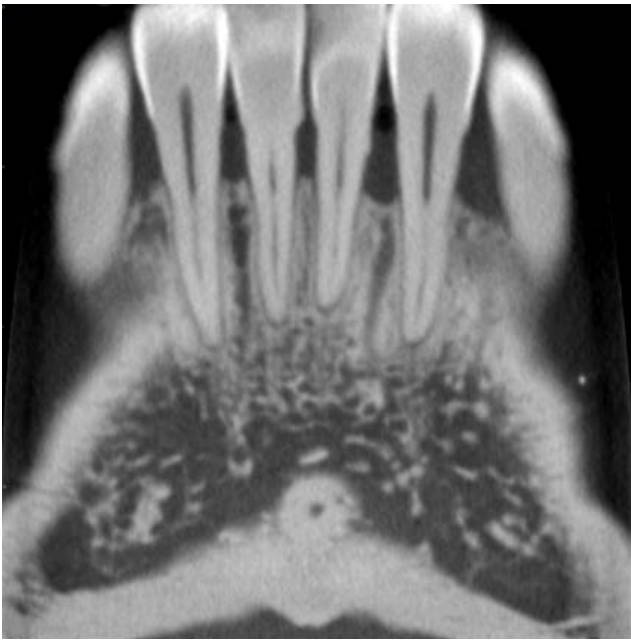

Image 2a: Para-coronal view

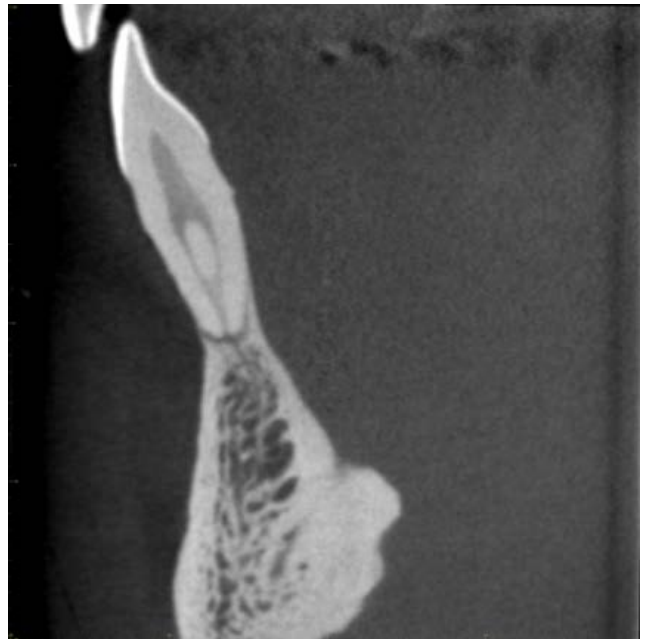


Image 2b: Cross-sectional view

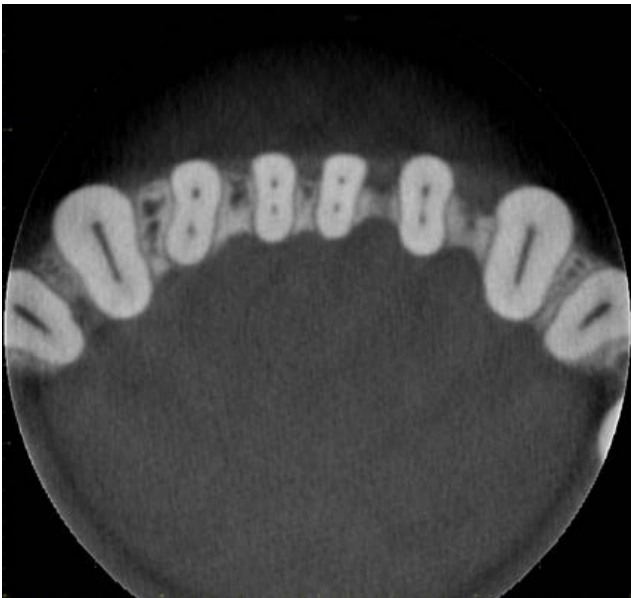


Image 2c: Axial view

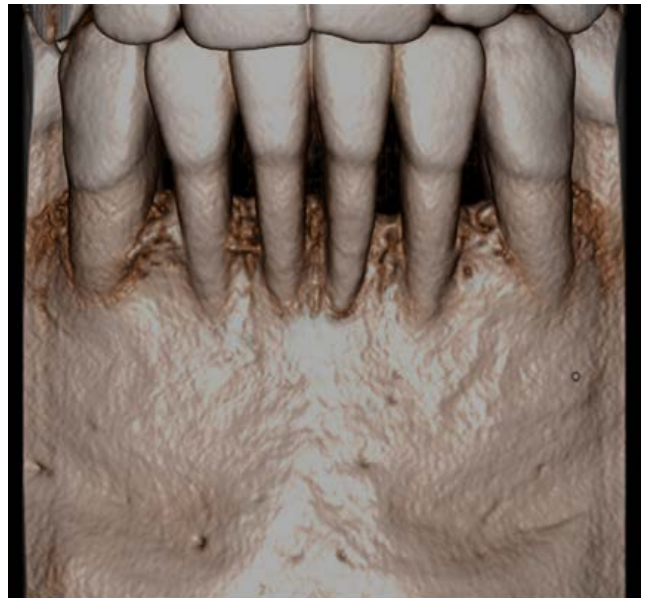


Image 2d: Volumetric Rendered view

An asymptomatic 51-year-old male presents with numerous complaints associated with the mandibular anterior teeth including unesthetic "black triangles" between the teeth, shrinking gums making the teeth look long, and "loose". The patient reports an extensive dental history of periodontal bone loss and therapy. A 4 cm x 4 cm FOV at 0.08 nominal voxel size was acquired and para-coronal (a), cross-sectional (b), axial (c), and three dimensional volumetric rendered (d) images clearly show the presence of calculus on the mandibular central incisors and generalized alveolar peri-circumferential radiographic bone loss extending to the middle third of the root and beyond consistent with a diagnosis of Periodontitis Stage III, localized incisor pattern. The patient was referred to a periodontist for management.

Endodontics

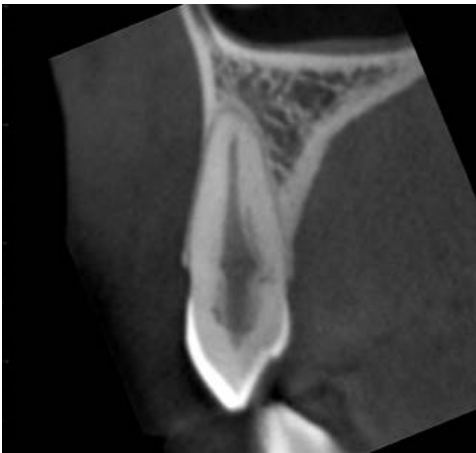


Image 3a: Cross-sectional view

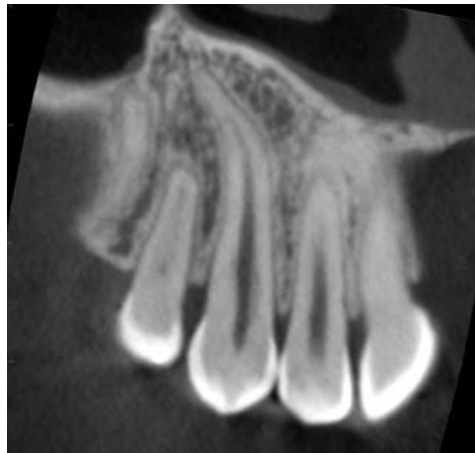

Image 3b: Para-sagittal view

An asymptomatic 27-year-old female presents immediately after fixed orthodontic appliance therapy with bitewing imaging showing diffuse radiolucent increase in the middle third of the pulp chamber of the maxillary right canine compared to the contralateral side. An 8 cm x 8 cm FOV at 0.25 nominal voxel size was acquired and a suspicious opacification of the pulp canal of the maxillary right canine noted on axial (a) images. A 4 cm diameter "zoom reconstruction" was performed at a nominal 0.08 mm voxel resolution centered on the maxillary canine. Cross-sectional (a), and para-sagittal (b) images clearly identify dentin resorption on the mesio-palatal aspect of the root extending peri-circumferentially around the pulp canal and chamber and loss of the root continuity at the level of the cervical third of the root indicative of Class III invasive cervical resorption. The patient was referred to an endodontist for management.

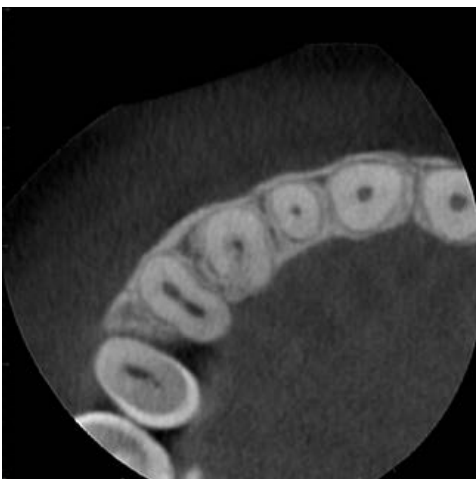

Image 4a: Axial view

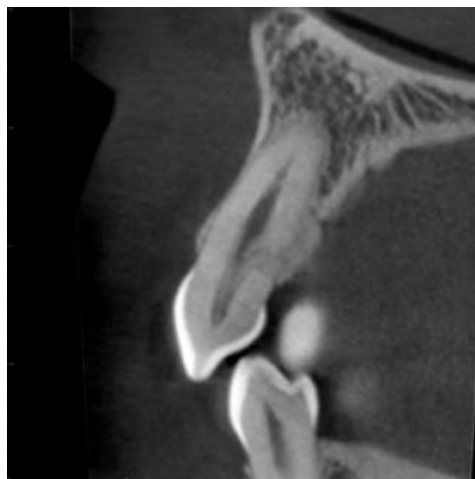

Image 4b: Cross-sectional view

A 24-year-old female presents with vague tooth sensitivity in the maxillary right region. Her dental history reveals active orthodontics more than 8 years previously involving extrusion of her right maxillary canine. Intraoral imaging is noncontributory. An 8 cm x 8 cm FOV at 0.25 nominal voxel size was acquired and a suspicious opacification of the pulp canal of the maxillary right canine noted. A 4 cm diameter "zoom reconstruction" was performed at a nominal 0.08 mm voxel resolution centered on the maxillary canine and these indications are noted on axial (a) and magnified cross-sectional (b) images. This image serves as a baseline for periodic, limited field, high resolution CBCT imaging to determine progression.

Oral Surgery

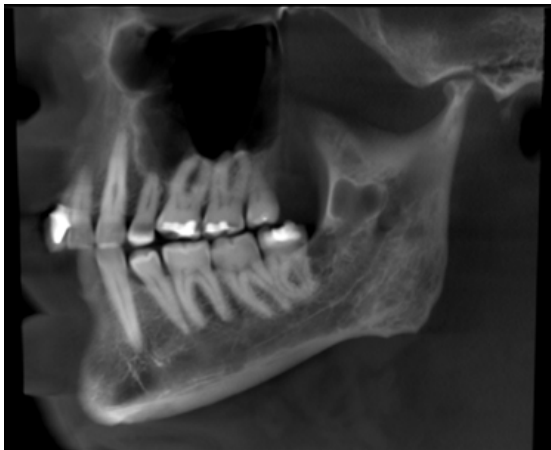

Image 5a: MPR Panoramic view

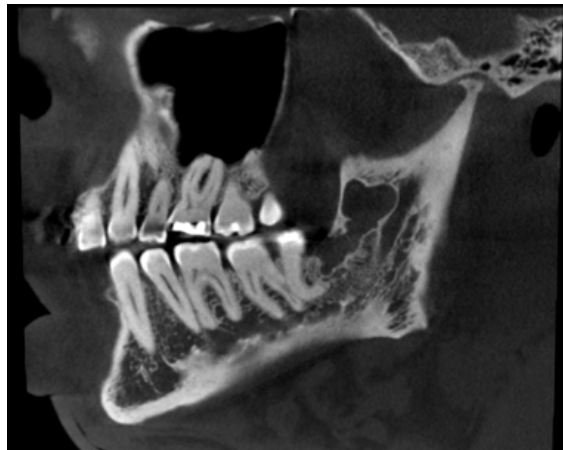

Image 5b: Para-sagittal view

An asymptomatic 56 year-year-old male presents with a history of incidental discovery of possible mandibular pathology in the left mandible on routine panoramic imaging taken 1 month previously. A 10 cm x 10 cm FOV at 0.25 nominal voxel size was acquired, A reformatted MPR panoramic (a), and para-sagittal (b) images clearly show a single, well-defined, corticated, irregularly-shaped bilobular low density lesion anterior to the lingula and mandibular foramen within the left ascending ramus with extension inferiorly through the intramedullary bone to include the entire alveolus posterior to the distal root of the left mandibular third molar. There is lingual cortical expansion but no perforation. The mandibular canal is intact throughout its course within the ramus and the mandible. The patient was referred to an oral surgeon and excisional biopsy reveals an odontogenic keratocyst.

Case courtesy, Drs William C. Scarfe and Gustavo Santaella, Louisville Kentucky

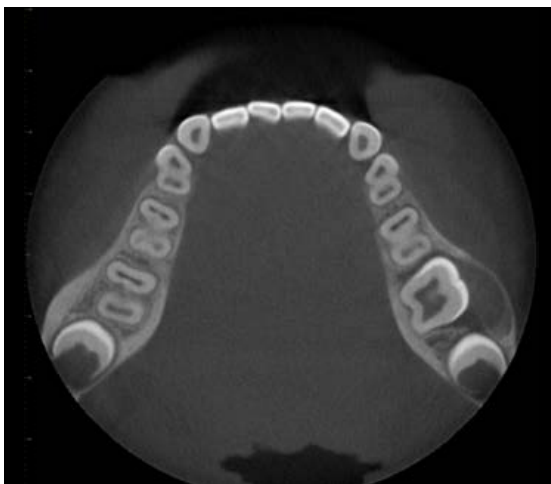

Image 6a: Axial view

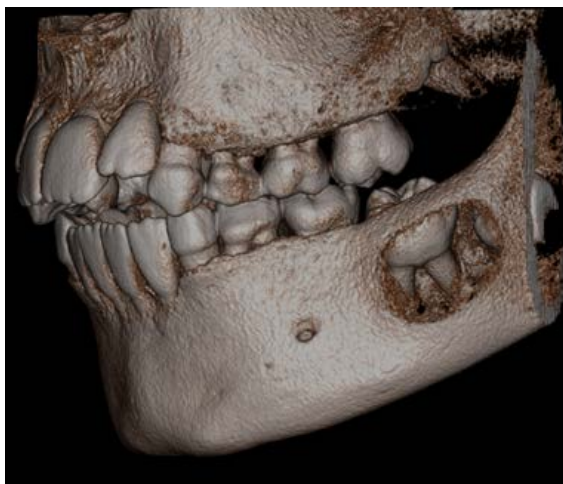
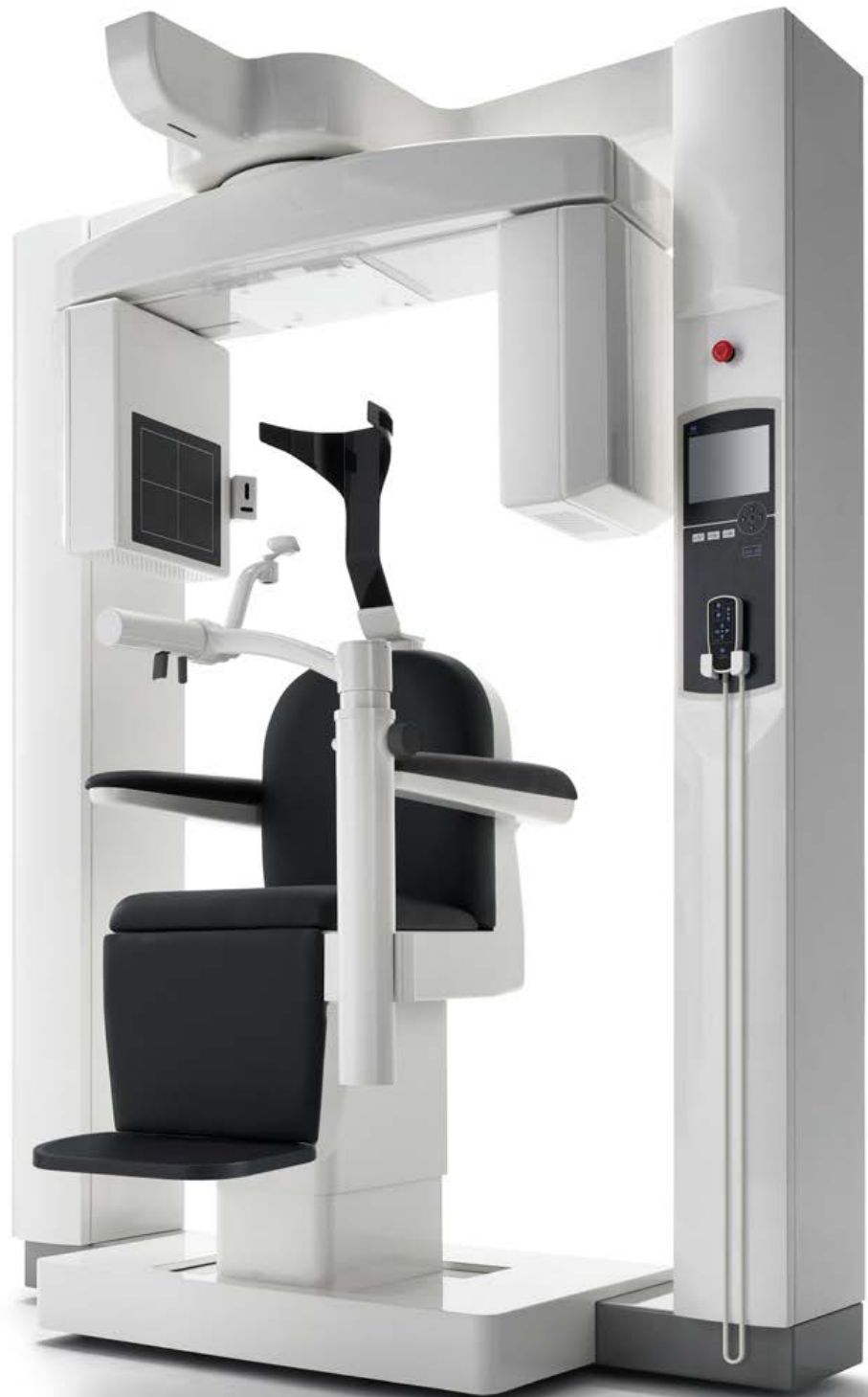
Image 6b: Volume Rendered view

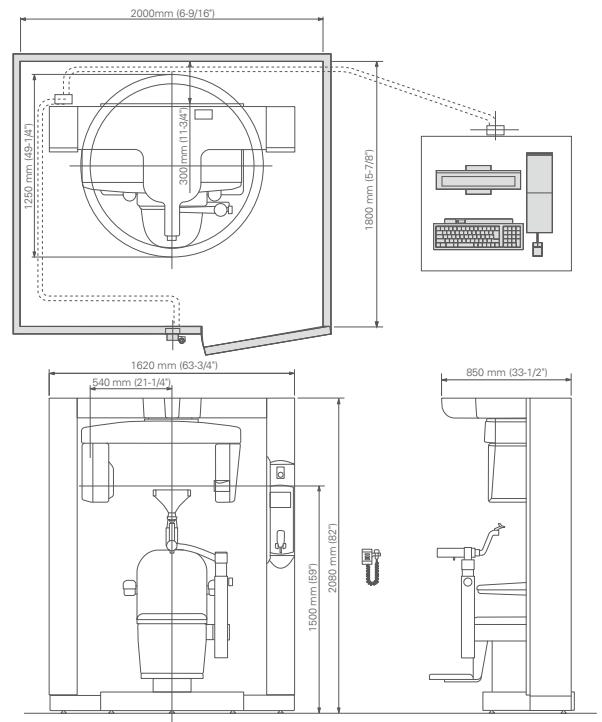
Buccal bifurcation cyst. Buccal localization of the lesion with an extended resorption of the vestibular cortical plate and a periosteal reaction.

Case courtesy, Prof. Dr. Reinhilde Jacobs, Center for Dentomaxillofacial Imaging, University Hospitals Leuven and Department of Imaging & Pathology, OMFS-IMPATh Research Group, KU Leuven, Leuven, Belgium



Specifications

Trade Name:	3D Accuotomo XYZ Slice View Tomograph
Model:	MCT-1
Type:	EX1/2 F17
Power Supply:	AC 100/ 110/ 120 V AC 220/230/240 VAC
Power Consumption:	max 2.0 kVA
Dimensions:	
Main Unit:	W1,620 mm x D1,250 mm x H2,080 mm (63-3/4" x 49-1/4" x 82")
Control Box:	W100 mm x D40 mm x H115 mm (4" x 1-5/8" x 4-1/2")
Weight:	Approx. 400kg (Approx. 882lbs)
X-ray Head	
Tube Voltage:	60-90 kV
Tube Current:	1-10 mA (Max 8mA : Hi-Fi, Hi-Res Mode)
Focal Spot Size:	0.5
Exposure Time:	Std Mode: 17.5 / 9.0 sec Hi-Fi Mode : 30.8 / 15.8 sec Hi-Res Mode : 30.8 / 15.8 sec Hi-Speed Mode : 10.5 / 5.4 sec
Field of View	ø 40 x H40 mm ø 60 x H60 mm ø 80 x H80 mm ø 100 x H50 mm ø 100 x H100 mm ø 140 x H50 mm ø 140 x H100 mm ø 170 x H120 mm
Voxel Size	80µm / 125µm / 160µm / 250µm



* X-ray protection should be provided for the patient when X-rays are emitted.
* Design and specifications are subject to change without notification.



Development and Manufacturing

J. MORITA MFG. CORP.

680 Higashihama Minami-cho, Fushimi-ku,
Kyoto 612-8533, Japan
T +81. (0)75. 611 2141, F +81. (0)75. 622 4595

Morita Global Website

www.morita.com

Distribution

J. MORITA CORP.

3-33-18 Tarumi-cho, Suita-shi, Osaka 564-8650, Japan
T +81. (0)6. 6380 1521, F +81. (0)6. 6380 0585

J. MORITA USA, INC.

9 Mason, Irvine CA 92618, USA
T +1. 949. 581 9600, F +1. 949. 581 8811

J. MORITA EUROPE GMBH

Justus-von-Liebig-Strasse 27b, 63128 Dietzenbach, Germany
T +49. (0)6074. 836 0, F +49. (0)6074. 836 299

MORITA DENTAL ASIA PTE. LTD.

150 Kampong Ampat
#06-01A KA Centre, Singapore 368324
T +65. 6779. 4795, F +65. 6777. 2279

J. MORITA CORP. AUSTRALIA & NEW ZEALAND

Suite 2.05, 247 Coward Street, Mascot NSW 2020, Australia
T +61. (0)2. 9667 3555, F +61. (0)2. 9667 3577

J. MORITA CORP. MIDDLE EAST

4 Tag Al Roasaa, Apartment 902, Saba Pacha 21311 Alexandria, Egypt
T +20. (0)3. 58 222 94, F +20. (0)3. 58 222 96

J. MORITA CORP. INDIA

Filix Office No.908, L.B.S. Marg, Opp. Asian Paints, Bhandup (West), Mumbai 400078, India
T +91-22-2595-3482

J. MORITA MFG. CORP. INDONESIA

28F, DBS Bank Tower, Jl. Prof. Dr. Satrio Kav. 3-5, Jakarta 12940, Indonesia
T +62-21-2988-8332, F + 62-21-2988-8201

SIAMDENT CO., LTD.

71/10 Mu 5, Thakham, Bangpakong, Chachuengsao 24130, Thailand
T +66. 38. 573042, F +66. 38. 573043
www.siamdent.com

Subject to technical changes and errors.

Diagnostic and Imaging Equipment

Treatment Units

Handpieces and Instruments

Endodontic System

Laser Equipment

Laboratory Devices

Educational and Training Systems

Auxiliaries